

*Parasitology and Helminthology*

## The Endoparasites (Pentastomida, Nematoda) of African Rock Python (*Python sebae* Gmelin, 1788) in Tbilisi Zoological Park

Lali Murvanidze\*, Tsitsino Lomidze\*, Ketevan Nikolaishvili\*

\*Institute of Zoology, Iliia State University, Tbilisi

(Presented by Academy Member Irakli Eliava)

**ABSTRACT.** The paper presents the data on the helminthological investigation conducted in 2010 and 2013 on two African rock pythons (*Python sebae* Gmelin, 1788) from Tansania preserved in Tbilisi Zoological Park. The material was supplied by the staff of the veterinary service of the Tbilisi Zoological Park. Three species of endoparasites were revealed in internal organs of the python, which died in 2010: the pentastome *Armillifer armillatus* (Wyman, 1848) - in the lung, and two species of ascaridoid nematodes were revealed in digestive system: *Ophidascaris filaria* (Dujardin, 1845) - in gastric mucous layer and *Polydelphis attenuata* (Molin, 1858) Baylis, 1921, in the intestine. The 13 individuals of *P. attenuata* (Molin, 1858) Baylis, 1921 were withdrawn from other python organism in 2013 as a result of dehelminthization. Description of parasites was made on the basis of morphological and morphometric data, obtained from both living material and fixed preparations. It is advisable to undertake special safety precautions to the captured animals in order to avoid lethal outcomes, caused by helminths in pythons living in isolation in zoological parks. Animals, newly introduced to zoological parks, should necessarily be subjected to dehelminthization and further parasitological monitoring. As there is a threat of disease with pentastomiasis the staff nurses, working in the terrarium, people under the risk should necessarily follow the safety precautions. © 2015 Bull. Georg. Natl. Acad. Sci.

**Key words:** African Rock Python (*Python sebae*), *Armillifer armillatus*, *Ophidascaris filaria*, *Polydelphis attenuata*.

Pythons, like other species of reptiles are intermediate, paratenic or definite hosts of a series of endoparasites. Life mode of pythons in terrain and aquatic ecosystems, versatile food chains, make preconditions for getting the eggs or larvae of helminths into their organism. Infestation of the *Python sebae* with helminths in Africa is associated by Aruo [1] with consumption of amphibians and

small mammals, living on the territory, adjacent to the water reservoir, which are intermediate hosts or carriers of these helminths. Pythons, introduced to zoological parks from natural coenoses often have serious diseases. They are often infested with zooparasites of epizootic significance, which may cause even death of the host organism. At the same time, it should be considered that pythons,

transferred to zoological parks from the natural coenoses are under the stress, their immune system is weakened and general condition worsened. In case of intensive invasion helminths also become stress-agents [2]. The zoo setting unarguably provides a platform for this [3]. In big, specialized zoos, where numerous reptiles are kept, infestation with helminths is one of the life-threatening problems. Information on such cases is abundant in scientific literature. N. Kamalov [4] names cestode *Bothriocephalus pythonis* (Retzius, 1829) as a causative agent of death of reticulate python - *Python reticulatus* in the Tbilisi Zoological Park; anorexia, caused by the nematode *Ophidascaris* made necessary to euthanize the python, living in the zoo in Atlanta; also anorexia, evoked by ascaridoid nematodes became the cause of death of reticulate python (*Python reticulatus*) in one of the zoos in India [5]. In the zoo in Nigeria [6] pythons were infested with specific nematode of hen *Ascaridia galli*, as they ate chicken; in Bangladesh [7] nematodes of the genus *Ophidascaris* were isolated from the gaster of the died python and different pathologies of intestinal tract were fixed. Hamir, [cited in 8], points to the case, when numerous fibrotic nodes were found on the walls of aorta and in the celome of the python, died in 3 weeks due to the anorexia. In each node one or more nematode being at larval stage were detected, whose adult forms were found in the intestine. The nematode was identified as *O. papuanus*. Great variety of species of ascaridoid nematodes was stated in *Python regius*, inhabitant of zoological park in Nigeria [3].

A wide range of works is dedicated to pentastomes (Pentastomidae) of pythons and the pathologies, caused by these parasites in animals and humans [11-13]. Tappe et al. [12] describe an interesting case of infestation with larval forms of pentastomes (*Armillifer armillatus*) of the dog, living in the snake nursery. Several months before this case, African python (*Python sebae*), infested with pentastomiasis (*A. arjmillatus*) died in this farm. They mention that pentastomiasis is a parasitic zoonosis with an increasing number of recognized human infections

in the West Africa. Heavy infection by nymphal pentastomes (*A. moniliformis*) in China is reported [14].

Pythons are introduced to the Tbilisi Zoological Park mainly from Africa, in particular Tanzania. African python (*Python sebae*, Gmelin, 1788), the most common species occurring in Africa [1], is characterized with wide spectrum of nutrition. Their diet in the Tbilisi Zoological Park consists of rabbits and hamsters mainly. Pythons living in the Tbilisi Zoological Park are under the constant monitoring of veterinarians and after certain periods are subjected to the dehelminthization, but despite the undertaken preventive measures their death sometimes is not possible to avoid. Here too, along with above noted stress conditions infectious or invasions diseases may become the cause of death. Such case took place in the Tbilisi Zoological Park in winter of 2008, when African python died a month later of its introduction to the zoo. Post-mortem investigation revealed the presence of the 96 cm long cestode *Bothridium pithonis* Blainville, 1824 in the small intestine of a reptile. Results of morphometric and biochemical investigation of a parasite were published by us in 2013 [15]. Several cases of infestation of pythons with endoparasites were revealed in the Tbilisi Zoological Park in the next years too.

## Materials and Methods

Here we present the results of helminthological investigations of two African pythons (*Python sebae* Gmelin, 1788), inhabitants of the Tbilisi Zoological Park, carried out in 2010 and 2013. Material for parasitological investigation was supplied by the veterinary service of the Tbilisi Zoological Park. One of these pythons died in January of 2010. The following parasites were detected in its internal organs: the pentastome *Armillifer armillatus* - in the lung; two species of ascaridoid nematodes in the intestinal tract: *Ophidascaris filaria* - 3 individuals in the gastric mucous membrane of and 2 individuals of *Polydelphis attenuata* - in the gut. All individuals of parasites were alive. In November of 2013 13

individuals were received – 12 females and 1 male of ascaridoid nematode species *Polydelphis attenuata*, isolated as a result of dehelminthization from another individual of the same species African python (*Python sebae* Gmelin, 1788) living in the Tbilisi Zoological Park. It should be noted that this individual of python is alive until now.

The parasites were washed in water, then in physiological solution, after microscopic investigation of alive individuals were fixed: pentastomida – in 70° alcohol; nematodes – in Barbagallo's solution (3% formalin+0.8% NaCl). For morphological studies the nematodes were fixed using the glycerine and lactic acid mixed at equal ratios. Descriptions were made on the basis of morphometric data, obtained from both, living and fixed preparations. All studied samples are preserved in the Laboratory of Parasitology of Ilia State University.

## Results and discussion

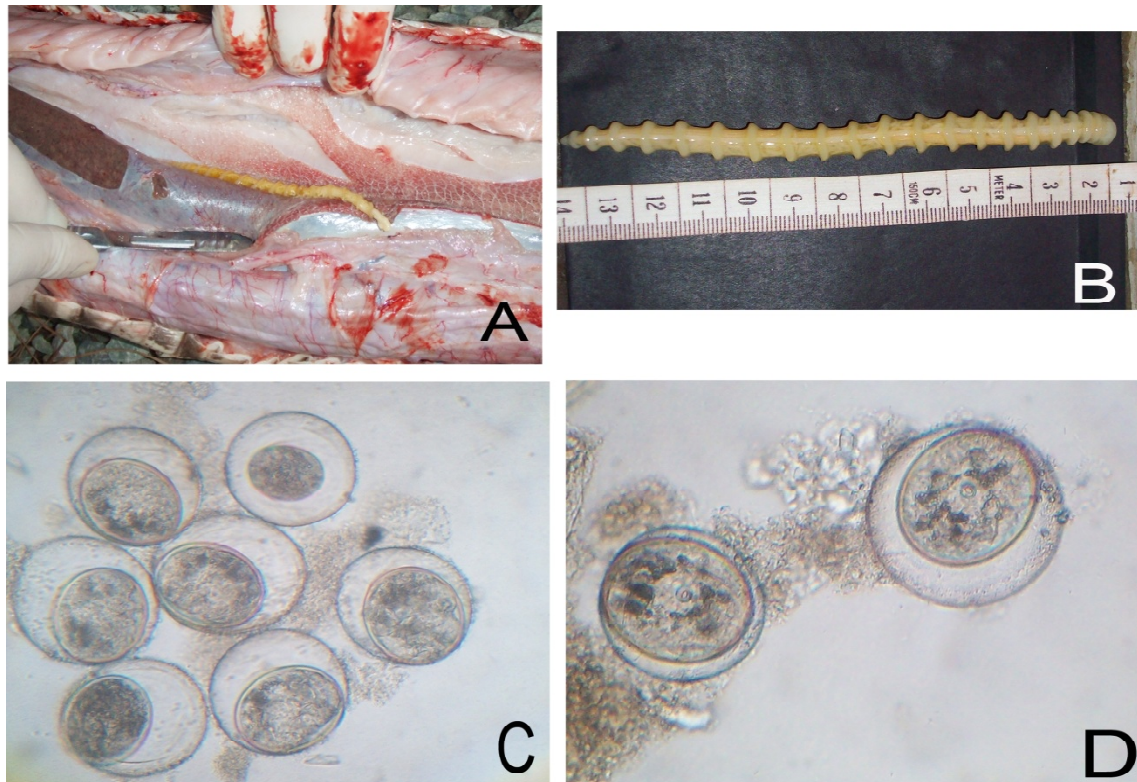
The 3 species of endoparasites were registered in two African pythons, living in the Tbilisi Zoological Park. One of them is the parasite of the lung and the rest two species are parasites of the digestive tract. All three species were found in the organism of the died python: pentastome - in the lung and two species of ascaridoid nematodes in the intestinal tract. Only one species of ascaridoid nematode was isolated as a result of dehelminthization from the another python, which is still alive.

**Pentastomes.** About 144 species and subspecies of endoparasites belong to pentastomids (Pentastomida, Crustacea), which are characterized by a wide range of hosts [16]. Genetic investigations showed that pentastomids are a group of modified crustaceans probably related to branchiurans, united in the type Pentastomida [17]. However, taxonomic position of this group of parasites is still debatable. Adult pentastomes are obligate parasites of respiratory organs of vertebrate animals, mainly serpents. They also parasitize mammals and birds. The majority of Pentastomes species are characterized by a heteroxenic cycle of development with

involvement of intermediate hosts. Paratenic hosts also play alternative transmission role in the distribution of pentastomes [18]. Predatory fish, amphibians, reptiles and micro mammals are considered to be paratenic hosts. The most common genera of pentastomes, occurring in reptiles are: *Armillifer* - (in pythons and other reptiles); *Porocephalus* (in boas and rattlesnakes); *Kiricephalus* (in colubrid snakes); *Sebekia* (in crocodilians) and *Raillietiella* (in lizards and snakes). Adult pentastomids are localized in the respiratory tract of reptiles, in lungs or under the skin, causing mechanical damage of these organs, inflammatory processes and, possibly, they may cause death of the host animal [9]. In tropical countries this is an unusual group of vermiform parasites that infect humans and animals. Human and animals are infested with nymphal pentastomiasis via the oral way, when consuming water or food polluted with parasite eggs, also due to unwashed hands and poor hygiene. Pythons are infested while feeding with intermediate hosts, diseased with nymphatic pentastomiasis (fish, small mammals, birds, etc.).

None of the representatives of Pentastomida in reptiles were detected in natural biocenoses of Georgia. Only cases of infection of mammals with *Linguatula*, belonging to this group, are reported for Georgia. Its mature adult forms were found in the nasal cavity of wolfs (3 cases) in Borjomi District [19] and nymphs – in parenchymal organs and mesenteric gland of wild ruminant animals (Daghestan tur - *Capra cylindricornis* Blyth.) and rodents (rabbit, black rat) [20], parenchymal organs of cattle, sheep and goats [19]. On the territory of Azerbaijan, adjacent to Georgia, nymphs of *Linguatula* were found in the lungs of the common turkey and the black kite - *Milvus migrans* [21].

The pentastome *Armillifer armillatus* (Wyman, 1848.) (Fig. 1, A, B) isolated by us is an adult female individual, whose uterus was full of eggs, being at different developmental stages (Fig. 1, C, D). Parasite length – 13 cm, width – at the widest place – 6 mm, at the segment – 9 mm, at the narrowest place, near the



**Fig. 1.** A, B – An adult female of *Armillifer armillatus* (Wyman, 1848) isolated from common African Rock Python - *Python sebae*; C - mature and immature eggs of *A. armillatus*; D - mature eggs.

tail – 2 mm. Number of segments – 19, head prolonged, rounded. Head length – 8 mm, width – 6 mm.

Coprological and parasitological examination carried out at the introduction of python to the zoo, did not reveal presence of eggs of Pentastomida, but at the post mortem examination of the python great number of eggs were fixed both in the uterus of an animal and its faeces. In our opinion the python was infested with pentastomes in its natural range, on the territory of Tanzania. Elaboration of eggs from the fertilized female started after introduction of the python to the Tbilisi Zoological Park.

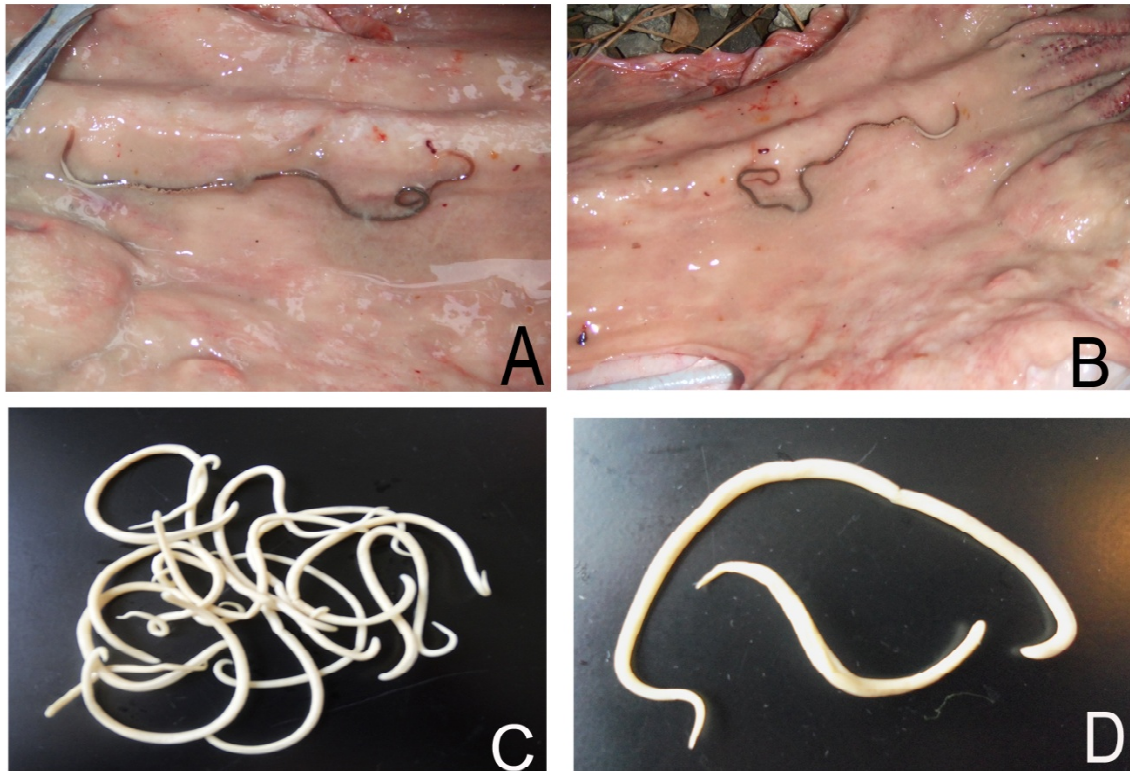
This was the first case of infestation of python with *A. armillatus* for Georgia.

**Ascaridoid nematodes.** Ascaridoid nematodes are very common helminths of pythons, though they are not distinguished by great specific diversity. Presence of only few genera of this group of nematodes is reported in pythons inhabiting Africa, America, Asian countries and Australia. Among them *Ophidascaris* Baylis, 1920, *Polydelphis* Baylis, 1920, *Amplicaecum*

Baylis, 1920 and *Hexametra* Travassos, 1920, are the most common. Adults embed in the gastric mucosa and larvae migrate through visceral tissues, creating mechanical damage [9, 22]. Very often infestation with roundworms causes death of snakes, especially pythons. They cause inflammatory processes in walls of the gaster and intestines, perforation of the gut wall, ileus with infarction of the small intestine, obstruction of the bile and pancreatic ducts, etc. [23].

Two species of ascaridoid nematodes, belonging to 2 genera - *Ophidascaris* Baylis, 1920 and *Polydelphis* Baylis, 1920 were identified in the parasitological material, picked from pythons, living in the Tbilisi Zoological Park.

Position of *Ophidascaris* among Ascaridoid nematodes is still debatable. Sprent [22, 24, 25] worked on nematodes for a long time. He revised the genus *Ophidascaris* and singled out five groups within the group, first of which - “filaria” group occurs in pythons and a key is provided for differentiating eight species [26]. The author concludes that



**Fig. 2.** A, B - *Ophidascaris filaria* (Dujardin, 1845) in the gastric mucosa of the common African Rock Python (photos are provided by the veterinary service of the Tbilisi Zoological Park; C - Entangled worms *Polydelphis attenuata* (Molin, 1858) Baylis, 1921 from *P. sebae*; D - Female and male worms *P. attenuata*.

*Ophidascaris* is a comparatively new step of evolution and, presumably, expansion of nematodes of this genus took place from the Central Africa to Asia, on the one side, and to the American continent on the other, and in different direction - towards Madagascar and Australia. More than 20 species of the genus *Ophidascaris* are described to date and identification of new species is still in progress [27].

*Ophidascaris filaria* (Dujardin, 1845), Baylis, 1921 (Fig. 2, A, B) – localization – gastric mucous membrane, isolated from the organism of the dead python. Intensity of infestation – 3 individuals (2 females, 1 male). The body is of brown color, dark brown around the tail; shape – cylindrical, narrowed at the head and the tail, very narrowed towards the head. Dimensions of the female individual: length – 198 mm, width – 1.1 mm in the frontal part and 1.8 in the caudal part, maximum length – 2 mm; length of the male – 148 mm, width – 0.6 mm in the frontal part and 1.5 mm in the caudal part; maximum width – 2 mm.

*Polydelphis attenuata* (Molin, 1858) Baylis, 1921 (Fig. 2, C, D) – localization – intestine; found in both examined pythons. Intensity of infestation in the dead python – 2 individuals (both females). In the second case a pile of parasites consisting of 13 individuals (12 females, 1 male) has been isolated from the alive python, isolated as a result of dehelminthization. Body of *P. attenuata* is whitish-creamy. The helminth is quite long; very thin in the frontal part, bent on the ventral side, which gradually widens towards the tail. The tail is rounded, smooth. Oral cavity is surrounded by 3 labia, whose length exceeds the width. Labia are of equal width at basal and top parts. Intermediate labia are absent. Gullet straight, without bulb. Dimensions of the female individual: length – maximum 127 mm, minimum - 90 mm; average - 112.5 mm. Length of the male – 56 mm. Male individuals have clearly protruded spiculae, whose length is 6 mm.

Ascaridoid nematodes were fixed in Georgia in



pythons, protected in the Zoological Park.

It is possible to avoid diseases in pythons, among them those caused by helminths, if we regularly carry out parasitological monitoring and dehelminthization of animals protected in Zoos. This will favour adaptation of exotic animals to the environment, unusual for them.

According to the existing opinion (Vasiliev, 2009) it is advisable that the animals, captured for the zoological parks are subjected to the immediate prophylactic treatments on site. We share this opinion and think, that it is absolutely necessary to carry out dehelminthization of animals newly introduced to the zoos and their further parasitological monitoring.

To avoid frequent lethal outcomes in pythons,

living in isolation in zoological parks, it is advisable to feed them with certified food, which is free of parasites.

As the curators of terrariums are under the threat of disease with pentastomiasis, it is necessary for staff nurses, being under the risk to follow the safety precautions.

Results of research were handed over to the veterinary service of the Tbilisi Zoological Park so that they can plan and execute preventive and curative measures.

**Acknowledgement.** The authors express their gratitude to the veterinary service of the Tbilisi Zoological Park for giving us access to parasitological materials from pythons.

### პარაზიტოლოგია და ჰელმინთოლოგია

## აფრიკული პითონის (*Python sebae* Gmelin, 1788) ენდოპარაზიტები (*Pentastomida*, *Nematoda*) თბილისის ზოოლოგიურ პარკში

ლ. მურვანიძე\*, ც. ლომიძე\*, ქ. ნიკოლაიშვილი\*

\*ილიას სახელმწიფო უნივერსიტეტი, ზოოლოგიის ინსტიტუტი, თბილისი

(წარმოდგენილია აკადემიის წევრის ი. ელიაშვილის მიერ)

ნაშრომში მოცემულია თბილისის ზოოპარკში მობინადრე, ტანზანიიდან შემოყვანილი 2 აფრიკული პითონის (*Python sebae* Gmelin, 1788), 2010 და 2013 წლებში ჩატარებული ჰელმინთოლოგიური გამოკვლევის შედეგები. მასალა მოწოდებულია ზოოპარკის ვეტსამსახურის თანამშრომლების მიერ. 2010 წელს დაღუპული პითონის შინაგან ორგანოებში აღმოჩნდა სამი სახეობის ენდოპარაზიტი: ფილტვში - პენტასტომიდა *Armillifer armillatus* (Wyman, 1848), საჭმლის მომნელებელ სისტემაში ორი სახეობის ასკარიდოიდული ნემატოდა. კერძოდ, კუჭის ლორწოვან გარსში *Ophidascaris filaria* (Dujardin, 1845), ნაწლავში *Polydelphis attenuata* (Molin, 1858) Baylis, 1921. 2013 წელს, იმავე სახეობის მეორე პითონიდან, დეჰელმინტიზაციის შედეგად გამოიდევნა 13 ეგზემპლარი – *P. attenuata* (Molin, 1858) Baylis, 1921. პარაზიტების აღწერა გაკეთდა როგორც ცოცხალი, ისე დაფიქსირებული პრეპარატებიდან მორფოლოგიური და მორფომეტრული მონაცემების საფუძველზე. თბილისის ზოოლოგიურ პარკში დაცულ პითონებში,

ზემოთ აღნიშნული ენდოპარაზიტები საქართველოში პირველად აღინიშნება. ზოოპარკებში იზოლირებულ პითონებში ჰელმინთებით გამოწვეული, გახშირებული ლეტალური შედეგების თავიდან ასაცილებლად, ალბათ, მიზანშეწონილი იქნება დაჭერილ ცხოველებში პროფილაქტიკური ღონისძიებების გატარება ადგილზე. ამასთან, აუცილებელია ზოოპარკებში ახლად შეყვანილი ცხოველების დეჰელმინთიზაცია და შემდგომი პარაზიტოლოგიური მონიტორინგი. ვინაიდან არსებობს პენტასტომიაზით დაინფიცირების საფრთხე ტერარიუმის მომვლელ პერსონალში, აუცილებელია პრევენციული უსაფრთხოების ნორმების დაცვა რისკ-ფაქტორის მქონე პირთა მიერ.

## REFERENCES

1. Aruo S.K. (1977) E. Afr. Wildl. J. **15**:159-163.
2. Vasilev D.B. (2000) Avtoreferat dissertacii kandidata veterinarnykh nauk, 185 str. (in Russian).
3. Egbedade A., Akinkuotu O., Jayeola O., Niniola A., Emmanuel N., Olugbogi E., Onadeko S. (2014) J. Vet. Sci., **12**, 3 : 26-30.
4. Kamalov N.G. (1948) Proceedings of the Tbilisi Zoological Park, **1**:83-84 (in Georgian).
5. Gnani Charita V., Dhilleswara Rao S., Prakash Arun S., Prasanth Babu A. (2012) Zoo's PRINT, **27**, 10:24-25.
6. Taiwo V.O., Alaka O.O., Sadiq N.A., Adejinmi J.O. (2002) Afr. J. Biomed. Res. **5**: 93-95.
7. Biswas D., Das Sh., Alim Md.A. (2014) Scholarly J. of Agricultural Sci., **4**, 1: 24-26.
8. Elliot Jacobson R. (2007) Parasites and Parasitic Diseases of Reptiles in "Infectious Diseases and Pathology of Reptiles", CRC Press, Taylor & Francis, 584 – 590.
9. Khalil G.M. (1972) J Egypt Public Health Assoc. , **47**:364–369.
10. Yapo Ette H., Fanton L., Adou Bryn K.D., Botti K., Koffi K. et al. (2003) Forensic Sci Int., **137**:52–54.
11. Dakubo J.C., Etwire V.K., Kumoji R., Naaeder S.B. (2006) West Afr J Med., **25**:166–168.
12. Tappe D., Büttner D.W. (2009) PLoS Negl Trop Dis.3:e320. DOI: 14.137/journal.pntd.0000320.
13. Tappe D., Meyer M., Oesterlein A., Jaye A., Frosch M., Schoen C., Pantchev N. (2011) Emerg. Infect Dis. **17**, 2: 251-254.
14. PAN Cun-mei, TANG Hong-feng, QIU Ming-hua and XIONG Qi-xing (2005) Chin Med. J., **118**, 3: 262-264.
15. Murvanidze L., Lomidze Ts., Nikolaishvili K. (2013) Bull. Georg. Natl. Acad. Sci., **7**, 1: 100-102.
16. Christoffersen M.L., De Assis J.E. (2013) Zool. Med. Leiden **87** (1): 29.
17. Lavrov D.V., Brown W.M., Boore J.L. (2004) Proc. Biol. Sci. 271 (1538): 537-44. DOI: 10. 1098/rspb. 2003. 2631.
18. Sharpilo V.P. (2003) Vestnik zoologii, **37**, 3: 75-78.
19. Kurashvili B., Rodonaia T., Matsaberidze G. et al. (1991) Parasitological investigations in biogeocoenoses of the Lesser Caucasus and Animal Farms. Tbilisi, p. 95, 199p. (in Georgian).
20. Rodonaia T. (1971) Helminths of hunting mammals of Georgia, Metsniereba, Tbilisi, p. 326, pp. 347-452 (in Georgian).
21. Vaidova S.M., Feizullaev N.A. (1959) Dokl. Acad. Nauk Azer. SSP, **5**: 423-424 (in Russian).
22. Sprent J.F.A. (1969a) Parasitology, **59**: 129-140.
23. Kutzer E., Grünberg W. (1965) Zentralblatt für Veterinarmedizin Reihe B,**12**, 2: 155-175; Issue published online: 13 May 2010.
24. Sprent J.F.A. (1969b) Parasitology, **59**: 937-959.
25. Sprent J.F.A. (1970) Parasitology, **60**: 375-397.
26. Sprent J.F.A. (1988) Systematic Parasitology, **11**, 3: 165-213.
27. Siqueira L.R., Panizzutti M.H.M., Muniz-Pereira L.C., Pinto R.M. (2005) Rev. Bras. Zool., **22**, 3: 587-590
28. Vasilev D.B. (2009) Gelmintozii reptilii v nevole i ikh lechenie. Forum My Reptile: Articles on diseases of reptiles (in Russian).

Received August, 2015